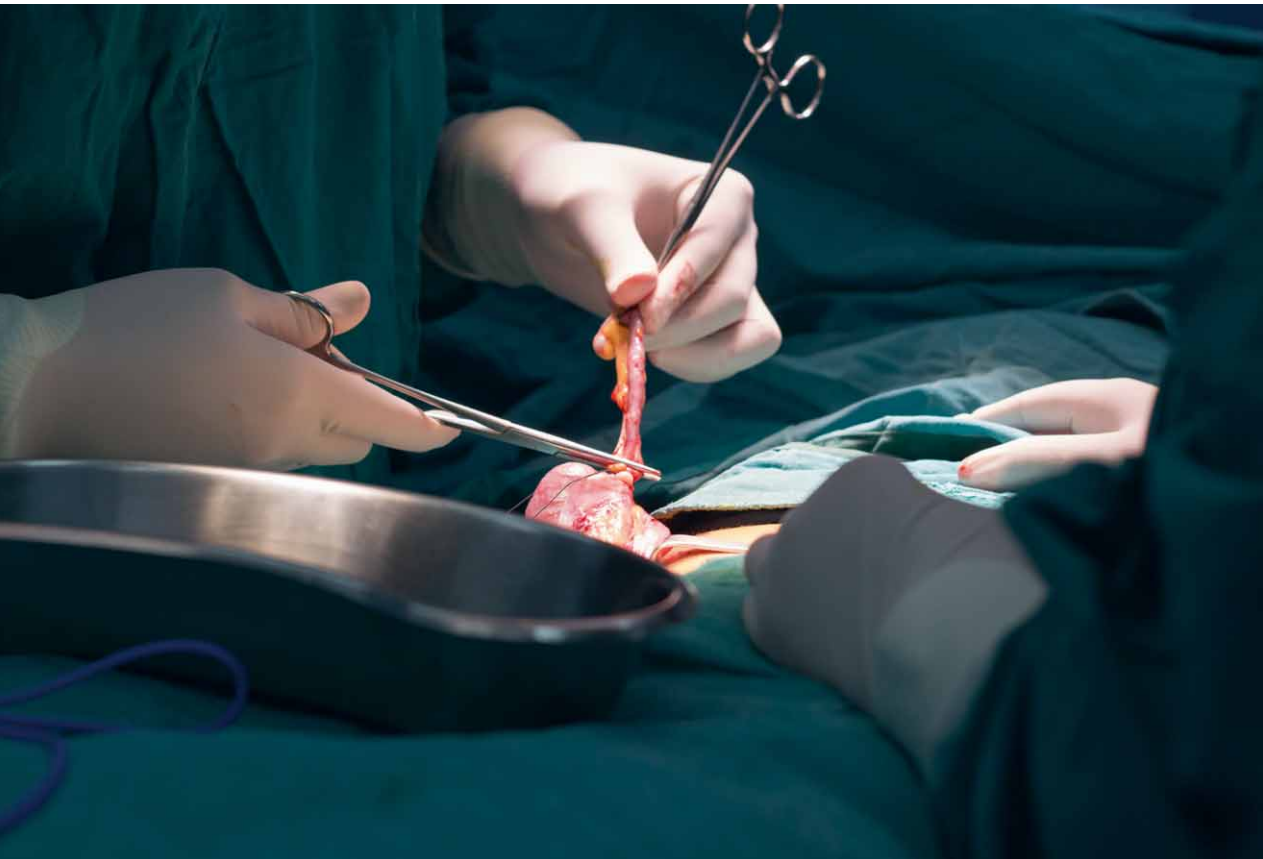


Vitezslav Marek, et al.

Acute appendicitis

early diagnosis and
preoperative consideration



Thanks for the support that made the publication possible belong
Beckman Coulter Slovenská republika s.r.o., EWOPHARMA spol. s r.o.,
Nadácia Železiarne Podbrezová, PASCOE Slovensko s.r.o.
a Združenie pre onkológiu – Onkologický ústav sv. Alžbety, s.r.o.



Vitezslav Marek, et al.

Acute appendicitis

early diagnosis and
preoperative consideration

Notice to readers and users of this book

All rights reserved. No part of this printed or electronic book may be reproduced or distributed in paper, electronic or other form without prior written permission from the publisher. Unauthorized use of this book will be prosecuted.

Vitezslav Marek, MD, PhD., prof. Stefan Durdik, MD, PhD.

Department of Surgical Oncology, St. Elizabeth Hospital, Medical School of Comenius University, Bratislava

ACUTE APPENDICITIS

early diagnosis and preoperative consideration

Reviews:

prof. Rudolf Hyrdel, MD, CSc.

prof. Marian Vidiscak, MD, Mgr., PhD., FEBPS

© Grada Publishing, a.s., 2021

Cover Photo © depositphotos.com, 2021

The publication of the professional book was approved by the Scientific Editorial Board of Grada Publishing, a.s.

Published by Grada Publishing, a.s.

U Pruhonu 22, Praha 7

ISBN 978-80-271-3342-0

as its 8321. publication

Editor-in-Chief: Helena Glezgova, Mgr.

Typography and Technical editing: Jan Sístek

Illustration Planner: Figures 8.1, 8.2, 8.13 to 8.16, 8.23, 8.25, 8.30 to 8.32 according to the author's drawings were redrawn by Jana Nejtkova

Number of pages: 117

1st edition, Bratislava, Praha 2021

The names of products, companies, etc. used in this book may be trademarks or registered trademarks of their respective owners, but this is not specifically indicated.

The procedures and examples in the book, as well as information on drugs, their forms, dosage and application, are compiled to the best of author's knowledge. Their practical application has no legal consequences for authors or publishers.

ISBN 978-80-271-4645-1 (pdf)

Contents

Preface	8
1 Case studies (<i>Vitezslav Marek</i>)	9
2 Definition and history (<i>Vitezslav Marek</i>)	20
3 Anatomy and physiology (<i>Vitezslav Marek</i>)	22
4 Epidemiology (<i>Vitezslav Marek</i>)	24
5 AA Classification (<i>Vitezslav Marek</i>)	26
5.1 Classification of AA according to surgical findings during laparotomy	26
5.2 Classification of AA according to surgical findings during laparoscopy	26
5.3 Classification of AA according to clinical, imaging and laparoscopic findings	27
6 Aetiology and pathophysiology of AA (<i>Vitezslav Marek</i>)	31
7 Histological classification and pathology of AA (<i>Vitezslav Marek</i>)	34
7.1 Macroscopic pathological-anatomical image of AA	34
7.2 Microscopic histological image of AA	35
7.3 Principles of pathological diagnostics of AA	38
8 Clinical course and image of AA (<i>Vitezslav Marek</i>)	40
8.1 Clinical symptomatology of the classical form of AA	41
8.1.1 Subjective signs	41
8.1.2 Overall objective symptoms	43
8.1.3 Local objective signs	44
8.1.4 Palpation signs	47
8.2 Clinical symptomatology of atypical forms of AA	68
8.3 Clinical symptomatology of AA complications	75
8.3.1 AA perforation	75
8.3.2 Clinical picture of perforated AA	78
8.3.3 Perforated AA in the abdominal cavity	78
8.3.4 Perforated AA in the pelvis	79
8.3.5 Periappendicular infiltrate (phlegmon)	79
8.3.6 Periappendicular abscess	80
8.3.7 Diffuse peritonitis	80
8.3.8 Post-inflammatory adhesions	80
8.3.9 Pylephlebitis	81
8.3.10 Sterility	81
8.3.11 Appendicitis in the appendix stump	81

9	Laboratory examination (<i>Vitezslav Marek</i>).....	83
10	Imaging examinations (<i>Vitezslav Marek</i>).....	85
10.1	Native abdominal X-ray in the standing position	85
10.2	Transabdominal sonography	86
10.3	CT examination of the abdomen	88
10.4	MRI examination of the abdomen in AA	90
10.5	How to indicate imaging tests	90
11	Scoring systems (<i>Vitezslav Marek</i>)	93
12	Diagnostic laparoscopy (<i>Vitezslav Marek</i>)	98
13	Differential diagnostics of AA (<i>Vitezslav Marek</i>)	100
13.1	Diseases of the abdominal cavity	100
13.2	Diseases of the thoracic cavity	102
14	AA from the point of view of a forensic expert (<i>Stefan Durdik</i>)	103
15	Preoperative considerations and management (<i>Vitezslav Marek</i>).....	106
15.1	Conservative treatment	106
15.2	Laparotomy and laparoscopic appendectomy	107
16	Perspectives in AA diagnostics (<i>Vitezslav Marek</i>)	111
	Abbreviations	112
	Register	113
	Summary	117

Motto:

“I know the day will come when one suffering from an unknown disease will entrust himself into the hands of physicists. They will not ask them anything; they will take the patient’s blood, determine certain constants, multiply them by each other, check all the data according to a logarithmic table and cure the patient with a single pill. However, when I get sick, I prefer to see an old doctor. He will look at me, feel my heartbeat, palpate the abdomen, listen to my chest. He will then light his pipe, cough, rub his chin and smile at me, to ease my pain. Of course, I admire science, but I also admire wisdom.”

Antoine de Saint-Exupéry

This publication is dedicated, with love, to my parents. They were always there,

by Vitezslav Marek

Preface

Dear readers,

We would like to present to you a new publication offering the latest knowledge in the field of early diagnostics and preoperative considerations related to acute appendicitis (AA). The initial examination of a patient with acute abdominal pain at the surgical outpatient clinic is essential, as it decides the patient's future. Acute appendicitis ranks among the most common Acute Abdominal Emergency (AAE) cases. Its course is uncertain, misleading, highly variable and despite many scientific advances in elucidating its pathophysiology and diagnostics, it can still surprise and catch even an experienced diagnostician off guard. The reason for writing this publication was the fact that several young women who had overcome a complicated, perforating appendicitis recently came to the surgical outpatient clinic and currently are having trouble becoming pregnant. Their sadness and sense of helplessness inspired us to emphasize the importance of early diagnosis and preoperative considerations in acute appendicitis. In the individual chapters of this publication, we analyse diagnostic examination methods. We emphasize the anamnesis and physical examination of the abdomen of a patient suspected of having AA, which currently is and in the near future will remain the cornerstone of the diagnostics of this insidious disease. We are trying to learn to understand the nature of individual clinical symptoms and thus comprehend the logic of diagnostics in clinical examination. The diagnosis of AA itself belongs to the surgeon; it is inadmissible to give up this task up and place it on the shoulders of a radiologist. A thorough physical examination of the abdomen not only leads to diagnosis of the disease but also teaches the surgeon about the accuracy, thoroughness and thinking over of each diagnostic-therapeutic step, which can then be used in surgery. In most cases, a thorough diagnostician is also a thorough surgeon. Preoperative considerations require, in addition to knowledge, a certain amount of experience. We have tried to design an algorithm for preoperative reasoning and considerations in a therapeutic indication. We are aware that it is advantageous for a young novice in surgery to meet a senior, experienced colleague at the department, who will introduce him/her to this issue. We dedicate the publication to medical students, general practitioners, paediatricians, surgeons and other colleagues for whom AA diagnostics are a common daily bread. It will be our great pleasure, if it is useful to them and helps them improve their diagnostics of this disease. Finally, we would like to thank Ing. Pavol Marek and Ing. Jana Kucerova for their help with the image and text documentation and prof. Rudolf Hyrdel, MD, CSc. (Comenius University) and prof. Marian Vidiscak, MD, Mgr., PhD., FEBPS (University of Cambridge) for their review of the work.

Bratislava 31. may 2021

Vitezslav Marek, Stefan Durdik

1 Case studies

Vitezslav Marek

Case Report No. 1

male, 22 years old, married, 1 child, employed as a turner

The patient complains of abdominal pain, anorexia and nausea. He is subfebrile. Abdominal pain started 6 hours ago in the epigastrium; later it moved to the right hypogastrium, and it becomes more intense with coughing.

Clinical examination

The patient arrives cautiously to the surgical outpatient clinic, holding the right hypogastrium with his right hand, climbing onto the diagnostic table is difficult for him due to intense abdominal pain. Upon palpation examination we identify palpable painfulness in the right hypogastrium in the area of McBurney's point, with peritoneal irritation (défense musculaire) indicated. Percussion in the area of the right hypogastrium is significantly painful, tympanic in the rest of the abdomen; peristalsis is weakened, almost disappeared. Examination per rectum: ampoule, Douglas space painless.

Patient's weight: 80 kg, Height: 180 cm

Axillary body temperature: 37.2 °C, Heart rate: 110/min, Blood pressure: 110/80 mmHg

Laboratory results

Haemoglobin: 140 g/l, Leukocytes: 13.8 g/l, CRP 50 mg/l, NLR 4.2, Procalcitonin 8 ng/ml, IL-6 14 ng/l

Biochemical examination of urine: negative

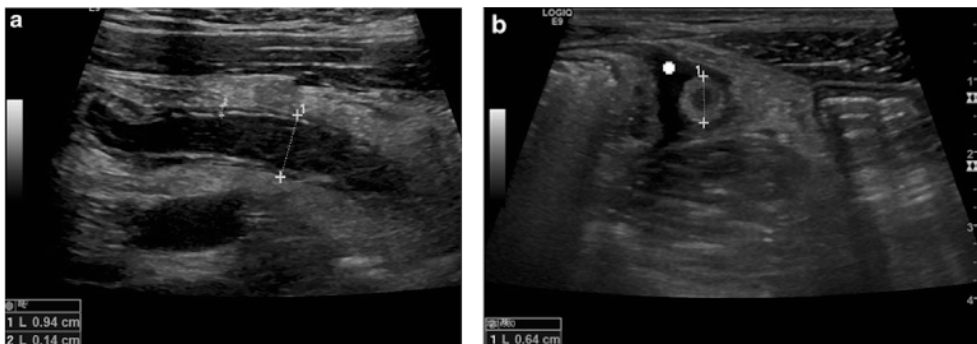


Fig. 1.1 Longitudinal (a) and transverse (b) US scan of acute appendicitis. Thickening of the wall (crosses 2), diameter > 6 mm (crosses 1) and free fluid surrounding the appendix (Assoc. Prof. Viera Lehotska, MD, PhD., Department of Radiology, St. Elizabeth Hospital, Medical School of Comenius University, Bratislava)

Transabdominal sonographic examination

Describes the diameter of the appendix – more than 6 mm, and free of fluid around the appendix.

Diagnosis

Acute appendicitis – surgical revision of the abdominal cavity indicated.

Management

Patient urgently admitted to the surgical department, peripheral vein found, hydration of the patient with crystalloid infusion solutions, oral food intake excluded. The patient underwent urgent surgery – laparoscopic appendectomy. Post-surgery course without complications, ATB not administered.

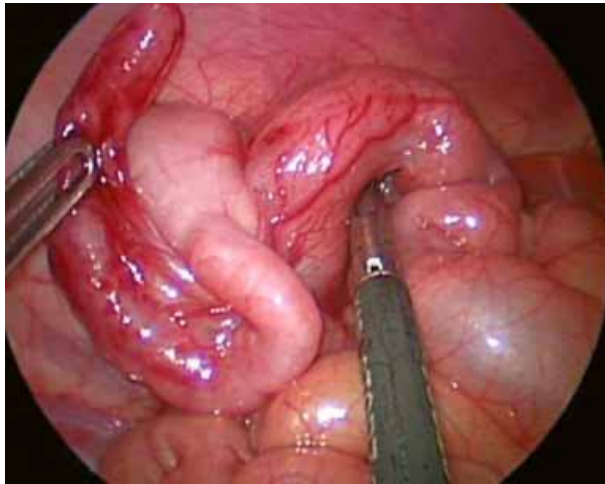


Fig. 1.2 *Acute phlegmonous appendicitis (Vitezslav Marek, MD, PhD., Department of Surgical Oncology, St. Elizabeth Hospital, Medical School of Comenius University, Bratislava)*

Histological examination

Phlegmonous appendicitis

Case Report No. 2

female, 30 years old, married, 2 children, employed as a primary school teacher

The patient complains of abdominal pain, vomiting and a febrile condition. Abdominal pain started 3 days ago in the right hypochondria; it is intensified by coughing.

Clinical examination

The patient enters the surgical clinic exhausted, vomiting repeatedly; she is dehydrated. On palpation, we identify a palpation pain in the right hypochondrium, Murphy's sign is negative. Tapotement of the right lumbar region is positive.

Abdominal percussion examination negative, peristalsis weakened, almost disappearing.

Examination per rectum: ampoule, Douglas space painless.

Clinical examination suspected hepatobiliary sepsis or pyelonephritis.

Patient's weight: 78 kg, Height: 173 cm

Axillary body temperature: 39.2 °C, Heart rate: 105/min, Blood pressure: 130/80 mmHg

Laboratory results

Haemoglobin: 125 g/l, Leukocytes: 14.5 g/l, CRP 115 mg/l, NLR 4.8, Procalcitonin 15 ng/ml, IL-6 21 ng/l

Biochemical examination of urine: blood +

Transabdominal sonographic examination of the abdomen

No pathological findings in the area of Morrison's pouch and signs of pelvic inflammation.

CT examination of the abdomen and pelvis

It described the collection of fluid in the subhepatic space and a long, retrocaecal appendix extending to the anterior right pararenal space.

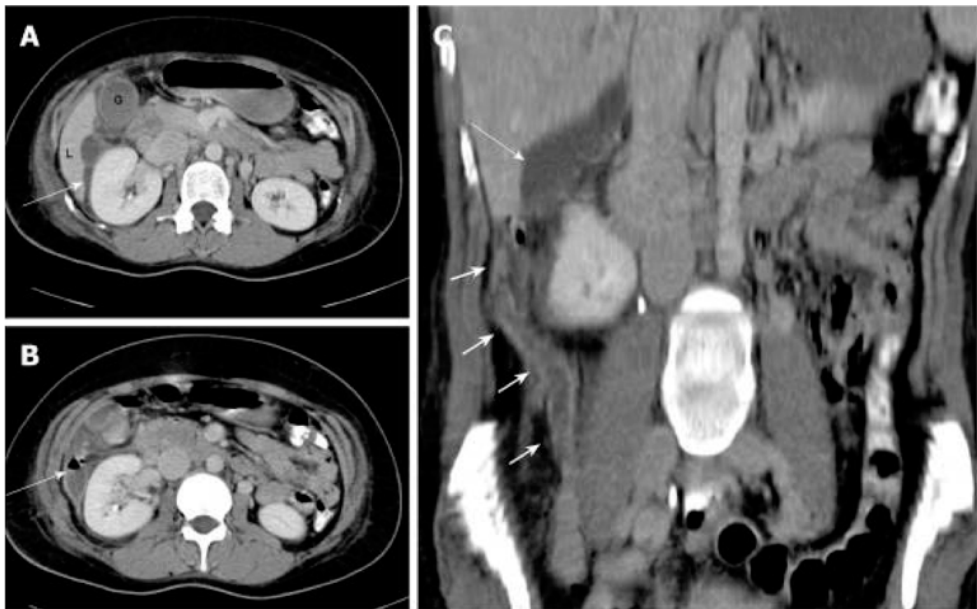


Fig. 1.3 *A – contrast-enhanced CT scan showing fluid collection (arrow) in the subhepatic region, extending anteriorly to the gallbladder fossa, B – the air fluid level in the collection adjacent to the right kidney, C – coronal reconstruction showing the long thickened and inflamed appendix (short arrows) reaching the subhepatic region, and the subhepatic collection (arrow) (Assoc. Prof. Viera Lehotska, MD, PhD.)*

Diagnosis

Retrocaecal, subhepatic appendicitis – surgical revision of the abdominal cavity indicated

Management

Patient urgently admitted to the ICU of the surgical department, central venous catheter (CVC) applied, hydration of the patient with crystalloid infusion solutions, oral food intake excluded, ATB treatment (amoxiclav + efloran i.v.) Urgent patient's surgery – open appendectomy, lavage and drainage of the abdominal cavity. Postoperative course without complications, ATB administered postoperatively for 7 days.

Histological examination

Gangrenous, retrocaecal, perforated appendicitis

Case Report No. 3*girl, 4 months old*

The patient, brought to the paediatric outpatient clinic with a muffled voice, crying; she is restless. Repeated vomiting and she has diarrhoea.

Clinical examination

The abdomen is in the niveau of the chest, palpably without abdominal pain and a protective spasm of the abdominal muscles, peristalsis is present, non-forced.

Patient's weight: 6.0 kg, Height: 61 cm

Axillary body temperature: 39.3 °C, Heart rate: 145/min, Blood pressure: 105/80 mmHg

Laboratory results

Haemoglobin: 135 g/l, Leukocytes: 12.0 g/l, CRP 76 mg/l, NLR 4.5, Procalcitonin 20 ng/ml, IL-6 43 ng/l

Biochemical examination of urine: negative

Chest X-ray examination

No pathological changes in the organs of the thoracic cavity

Transabdominal sonographic examination of the abdomen

No clear pathology in the abdominal cavity.

Diagnosis

Pyelonephritis susp.

Management

Patient urgently admitted to the paediatric ward, peripheral vein found in the frontal area of the head, hydration of the patient with crystalloid infusion solutions, antipyretics. Orally administered fluids, ATB: 3rd generation of Cephalosporin.

24 hours after admission, the clinical findings worsen. The child vomits repeatedly, the abdomen is distended. On palpation, we have found signs of peritoneal irritation.

X-ray native abdomen

Distended curves of the small intestine, without layers

Follow-up transabdominal sonographic examination of the abdomen

An incompressible 8 mm structure is present in the right hypogastrium, without fluid collection in its vicinity.

Surgical intervention: laparoscopic appendectomy.

Post-surgical course uncomplicated, ATB not administered post-surgically.

Histological examination

Phlegmonous appendicitis

Case Report No. 4

boy, 5 years old

Patient brought to a paediatric outpatient clinic with convulsive abdominal pain, repeated vomiting of stomach contents. Stool is regular, of firm consistency, diarrhoea is not present.

Clinical examination

The abdomen is slightly above the chest level, palpable pain is localized periumbilically, with no signs of peritoneal irritation, peristalsis is weakened, audible.

Patient's weight: 23 kg, Height: 110 cm

Axillary body temperature: 38.3 °C, Heart rate: 142/min, Blood pressure: 85/50 mmHg

Laboratory results

Haemoglobin: 125 g/l, Leukocytes: 17.3 g/l, CRP 71.6 mg/l, NLR 4.2, Procalcitonin 22 ng/ml, IL-6 35 ng/l

Biochemical examination of urine: negative

Transabdominal sonographic examination of the abdomen

No clear pathology in the abdominal cavity.

Diagnosis

Acute gastroenteritis susp.

Management

Patient urgently admitted to the paediatric ward. Peripheral vein found, hydration of the patient with crystalloid infusion solutions, antipyretics. Orally administered fluids, ATB: 3rd generation of Cephalosporin.

12 hours after admission, abdominal pain persists. Abdominal distension and constipation occur. There are no signs of peritoneal irritation on palpation.

Follow-up transabdominal sonographic examination of the abdomen

A striped formation 25.6 mm long, 9.4 mm wide, is present in the right hypogastrium.

X-ray native abdomen standing

Hydroaeric formations in the right hypogastrium.

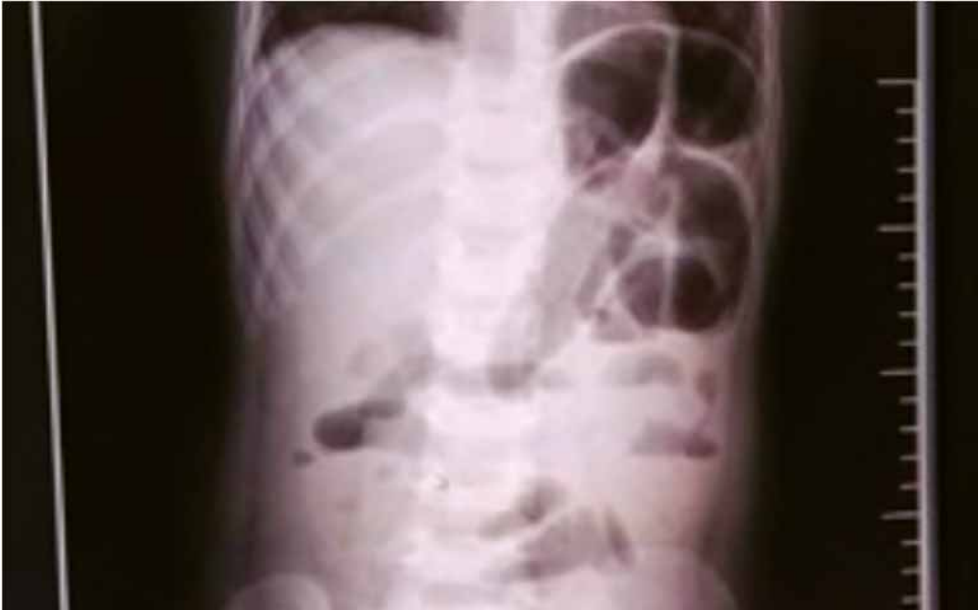

Fig. 1.4 Abdominal X-ray showing air-fluid level or gas deposition on the right lower quadrant abdomen (Prof. Stefan Durdik, MD, PhD., Department of Surgical Oncology, St. Elizabeth Hospital, Medical School of Comenius University, Bratislava)

Based on imaging examination, acute appendicitis is suspected. Immediate surgery indicated – laparoscopic appendectomy.

Postoperative course uncomplicated, ATB not administered postoperatively.

Histological examination

Phlegmonous appendicitis

Case Report No. 5

female, 64 years old, married, 2 children, pensioner

The patient comes to the surgical outpatient clinic with palpable tumorous resistance in the right hypogastrium, formed 2 months ago when lifting a mattress. Over the last 2 weeks, the resistance has increased and become sensitive to touch and coughing. She did not vomit, without signs of nausea. The stool is regular. She gave birth 43 years ago via gasterhysterotomy.

Clinical examination

The patient arrives to the surgical clinic calmly, she does not complain of abdominal pain when moving. Redness and a warming of the skin is visible in the area of the right hypogastrium. On palpation of the abdomen we found a tumorous resistance with mild pain in the right hypogastrium, without signs of peritoneal irritation. The percussion is painful in the right hypogastrium and tympanic in the rest of the abdomen. During auscultation, we found weakened, almost disappeared, peristalsis. Examination per rectum: ampoule, Douglas space painless.

Patient's weight: 98 kg, Height: 172 cm

Axillary body temperature: 37.4 °C, Heart rate: 111/min, Blood pressure: 105/80 mmHg

Laboratory results

Haemoglobin: 138 g/l, Leukocytes: 13.0 g/l, CRP 167.3 mg/l, NLR 4.8, Procalcitonin 35 ng/ml, IL-6 87 ng/l

Biochemical examination of urine: negative

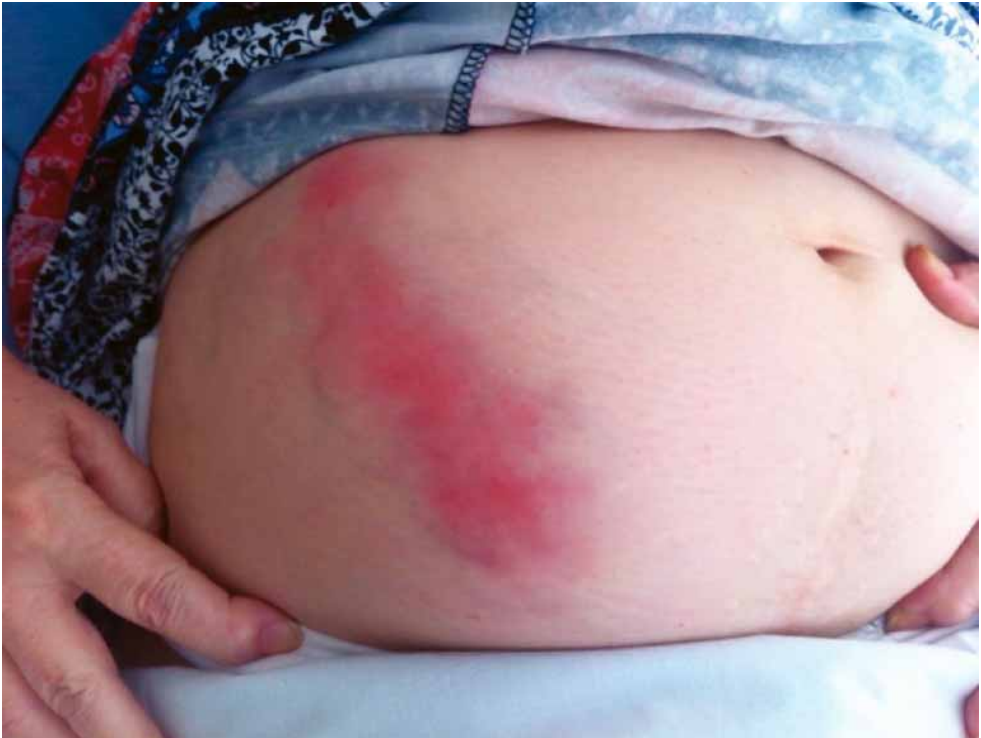

Fig. 1.5 *The patient's abdomen (1)*

CT examination of the abdomen and pelvis

In the right hypogastrium, there is an abscess measuring 140 × 70 mm located in the subcutaneous tissue. Inflammatory changes present in the locality of the appendix communicating with the abscess by an enterofascial fistula.